

SURGICAL PATHOLOGY

“BIOPSY”

IN ORAL SURGERY

This series of booklets are directed to undergraduate dental students and GDP. The booklets are aimed to serve as an outline guide to the user during reading in more comprehensive textbooks.

FOREWORD



Biopsy technique is among the key clinical skills imparted to a dentist during training as it has great bearing on successful diagnosis of various oral conditions. Dental practitioners who undertake this procedure without putting into consideration the key principles involved could miss the opportunity to diagnose a serious condition such as a malignancy until it is too late. Although the use of biopsy to assist in diagnosis is widely used in all medical fields, the procedure is not widely used in dental practice. This is mainly because of lack of awareness of its importance and the relevant techniques among dental practitioners.

This book acquaints the dental student and the general dental practitioner with the essential basic information that would assist them decide on whether to take a biopsy, and if so, the proper surgical techniques for the biopsy procedure.

Dr. Ochiba M. Lukandu BDS, PhD
HOD, Oral, Maxillofacial, Oral Medicine, Oral Radiology
And Oral Pathology Dept.
SOD, MU



This issue prepared and printed by:
Prof. Maged Lotfy,
Pyramids award coordinator and cosponsor
March 2016

CONTENT

INTRODUCTION TO DIAGNOSTIC PATHOLOGY	4
• History of specific lesion	4
CLINICAL EXAMINATION	6
PREBIOPSY MONITORING	10
BASIC PRINCIPLES OF FOLLOW-UP AND REFERRAL	13
• Biopsy or Referral	13
INSTRUMENTATION	
• Incising tissues	15
• Cutting tissues (scissors)	17
• Grasping tissues	17
SOFT TISSUES BIOPSY TECHNIQUES	
• Incisional biopsy	19
• Excisional biopsy	19
• Tissue stabilization	22
• Hemostasis	24
• Wound CLOSURE	24
HANDLING THE SPECIMEN	26
• TAGGING THE BIOPSY	27
• BIOPSY SUBMISSION FORM	27
ORAL BIOPSY (WHY, WHEN AND HOW)	30
REFERENCES, FURTHER READINGS AND LINKS	44

INTRODUCTION TO DIAGNOSTIC PATHOLOGY

Dentists often find oral soft tissue abnormalities when examining their patients. Some of these abnormal findings can be diagnosed based on their appearance and history, whereas others require more diagnostic steps. One available option to reach a diagnosis is the performance of a biopsy; namely, taking tissue for examination under a microscope.

HISTORY OF THE SPECIFIC LESION

It is generally accepted in medicine that many systemic diseases (up to 90%) can be diagnosed by gathering a detailed medical history. The same can be true of many oral lesions when the diagnostician is familiar with the natural history of the more common diseases. Questioning the patient who has a potentially pathologic condition should include the following:

1. *How long has the lesion been present?*

- A lesion that has been present for several years might be congenital and is more likely benign.
- A rapidly developing lesion is considered more ominous.
- Duration must be taken in context with other elements of the history because the lesion might have been present for an extended period before the patient became aware of its presence.

2. *Has the lesion changed in size?*

- A change in the radiographic or clinical size of a lesion, or both must determine.
- An aggressive, enlarging lesion is more likely to be malignant
- A slower-growing lesion suggests a possibly benign lesion.

By combining information on the growth rate with findings regarding the duration , one can make a more accurate assessment of the nature of the lesion.

3. *Has the lesion changed in character or features?*

- Noting changes in the physical characteristics of a lesion often can assist in the diagnosis. (e.g., a lump becoming an ulcer or an ulcer starting as a vesicle)
- For example, if an ulcer began as a vesicle, then it could suggest a localized or systemic vesiculobullous or viral disease.

4. *What symptoms are associated with the lesion?*

For example, pain, altered function, anesthesia or paraesthesia abnormal taste or odors, dysphagia, tenderness of cervical lymph nodes

- If painful, is the pain acute or chronic, constant or intermittent. What increases or decreases the pain.
- Lesions with an inflammatory component are most often associated with pain.
- Cancers, believed by many to be painful, actually are typically painless unless secondarily infected.
- Sensory nerve changes, such as numbness or tingling, often occur with a malignant or inflammatory process unless other identifiable causes can be ascertained.
- Swelling often can result from and occur with oral lesions, indicating an expansile process from any number of causes, including inflammation, infection, cysts, or tumor formation. The patient might indicate a sensation of fullness even before the doctor can actually visualize or verify the swelling during clinical examination.
- Painful lymph nodes usually indicate an inflammatory or infectious cause, but also can be a manifestation of malignancy.

5. What anatomic locations are involved?

Certain lesions have a predilection for certain anatomic areas or tissues.

- Noting whether the lesion is confined to keratinized or non-keratinized tissues, regions with salivary gland tissues, or areas of neural or vascular anatomy sometimes can provide clues to the diagnosis.

6. Are there any associated systemic symptoms?

The dentist should look for possible relations or manifestations from related systemic diseases or conditions.

- For example, many systemic viral conditions (e.g., measles, mumps, mononucleosis, herpes, and acquired immunodeficiency syndrome) can cause oral manifestations concurrent with the systemic involvement.
- Autoimmune conditions also can manifest with oral lesions.
- Many oral ulcerative conditions also can present lesions elsewhere in the body (e.g., pemphigus, lichen planus, erythema multiform, sexually transmitted infections).
- Other factors could include drug abuse or injuries from domestic violence.

7. Is there any historical event associated with the onset of the lesions?

For example, trauma, recent treatment, exposure to toxins or allergens, or visits to foreign countries

- One of the initial steps the dentist should take when a lesion is noted is to seek a possible explanation based on the patient's medical, dental, family, or social histories.
- Frequently, oral and perioral lesions can be caused by parafunctional habits, hard or hot foods, application of medications not intended for topical use, recent trauma, conditions involving the dentition (eg, caries, periodontal disease, fractured teeth), or an identified event or exposure. ■

CLINICAL EXAMINATION

When a lesion is discovered, careful clinical, radiographic examinations and palpation of regional lymph nodes are mandatory. Once the examination is complete, a detailed description of all objective and subjective findings should be documented in the patient's chart. A drawing or a graphic schematic of the location, orientation, general shape, and dimensions of the lesion in the patient record is helpful. The use of standardized illustrations can simplify the documentation. In addition, good-quality digital photographs are useful for documentation and can aid the pathologist. Details, descriptions, and drawings allow the dentist or subsequent referral specialists to evaluate the course of the lesion over time and determine whether it is enlarging, its features are changing, or if new lesions are appearing in different anatomic areas.

An examination is classically described as a process that includes inspection, palpation, percussion, and auscultation. In the head and neck region, inspection and palpation are more commonly used as diagnostic modalities, with inspection always preceding palpation. Early inspection facilitates creating a description of the lesion before it is handled because some lesions are so fragile that manipulation of any kind might result in hemorrhage or rupture of a fluid-filled lesion or loss of loosely attached surface tissues, which would compromise any subsequent examinations. Percussion is reserved for examination of the dentition. Auscultation is used infrequently but is important when examining for suspected vascular lesions.

The following list includes some important additional points to be considered during the inspection of a lesion:

1. **Anatomic location.**

Pathologic lesions can arise from any tissue within the oral cavity, including the epithelium, subcutaneous and submucosal connective tissues, muscle, tendon, nerve, bone, blood vessels, lymphatic vessels, or salivary glands.

The dentist should attempt to ascertain, as much as possible, which tissues are contributing to the lesion, based on the anatomic location of the lesion:

- For example, if a mass appears on the dorsum of the tongue, then the dentist would logically consider an epithelial, connective tissue, lymphatic, vascular, glandular, neural, or muscular origin.
- A mass on the inner aspect of the lower lip would prompt the dentist to include a minor salivary gland origin in the differential diagnosis, in addition to a connective tissue origin and other possibilities.

- Certain lesions can have unique anatomic characteristics, such as the linear tendencies of herpes zoster lesions as they follow neural pathways.
- Pulpal, periapical, and periodontal pathologic or inflammatory conditions also cause a large percentage of oral lesions.
- The role of trauma should always be entertained as a possible source of the lesion (ill-fitting dental appliances, parafunctional habits such as cheek biting, sharp edges on teeth or restorations, trauma from acts of domestic or other types of violence).

2. Overall physical characteristics.

Appropriate medical terminology should always be used to describe clinical findings in the record because terminology can be misleading and nonspecific.

- Terms such as ulcer or nodule might be interpreted differently by different examiners. Table 1 lists several common physical descriptions that are useful in describing oral and maxillofacial pathologic entities. Lay terms such as swelling and sore are generally not helpful and could be subject to misinterpretation.

3. Single versus multiple.

- The presence of multiple lesions is an important feature. When multiple ulcerations are found within the mouth, the dentist should think of specific possibilities for the differential diagnosis. To find multiple or bilateral neoplasm in the mouth is unusual, whereas vesiculobullous, bacterial, and viral diseases commonly present such a pattern. Similarly, an infectious process can exhibit outward spread because lesion infects the adjacent tissues with which it has had contact.

4. Size, shape, and growth.

- The size of the lesion should be measured and documented.
- The shape of the lesion also should be noted, whether the lesion is flat or slightly elevated, endophytic (growing inward) or exophytic (growing outward) from the epithelial surface, and sessile (broad based) or pedunculated (on a stalk).

5. Surface appearance.

- The epithelial surface of a lesion can be smooth, lobulated (verruciform), or irregular.
- If ulceration is present, then the characteristics of the ulcer base and margins should be recorded. Margins of an ulcer can be flat, rolled, raised, or everted.
- The base of the ulcer can be smooth, granulated, or covered with fibrin membrane, slough, or hemorrhagic crust (scab) or can have the fungating appearance that is characteristic of some malignancies.

6. Color.

The surface color(s) of a lesion can reflect various characteristics and even the origin of many lesions.

- A dark bluish swelling that blanches on pressure suggests a vascular lesion.
- A lighter-colored, bluish lesion that does not blanch might suggest a mucus-retention cyst.

TABLE 1. DESCRIPTIVE PATHOLOGY TERMS

- **Bulla:** A blister; an elevated, circumscribed, fluid containing lesion of skin or mucosa.
- **Crust:** (crusted): dried or clotted serum on the surface of the skin or mucosa.
- **Dysplasia:** any abnormal development of cellular size, shape, or organization in tissue.
- **Erosion:** a shallow superficial ulceration.
- **Hyperkeratosis:** an overgrowth of the cornified layer of epithelium.
- **Hyperplasia:** an increased number of normal cells.
- **Hypertrophy:** an increase in size caused by an increase in the size of the cell, not the number of cells.
- **Keratosis:** an overgrowth and thickening of cornified epithelium.
- **Leukoplakia:** a slowly developing change in mucosa characterized by firmly attached thickened white patches.
- **Macule:** a circumscribed non-elevated area of color change that distinct from adjacent tissues
- **Malignant:** anaplastic; a cancer that is potentially invasive and metastatic.
- **Nodule:** a large elevated circumscribed solid, palpable mass of skin or mucosa
- **Papule:** a small, elevated, circumscribed solid palpable mass of skin or mucosa.
- **Plaque:** any flat, slightly elevated superficial lesion.
- **Scale:** a thin compressed, superficial flake of cornified (keratinized) epithelium.
- **Stomatitis:** any generalized inflammatory condition of the oral mucosa.
- **Ulcer:** a crater-like circumscribed surface lesion resulting from necrosis of epithelium.
- **Vesicle:** a small blister: a small circumscribed elevation of skin or mucosa containing serous fluid.

- A pigmented lesion within the mucosa can suggest a “traumatic tattoo” of restorative material or a more ominous melanotic tumor.
- Keratinized white lesions can reflect a reaction to repetitive local tissue trauma or represent potentially premalignant changes.
- An erythematous (or mixed red-and-white) lesion can represent an even more ominous prognosis for dysplastic changes than a white lesion.
- Inflammation can be superimposed on areas of mechanical trauma or ulceration, resulting in a varied color from one examination to the next.

7. Sharpness of borders and mobility.

- If a mass is present, then the dentist should determine whether it is fixed to the surrounding deep tissues or freely movable.
- Determining the boundaries of the surface lesion will aid in establishing whether the mass is fixed to adjacent bone, arising from bone and extending into adjacent soft tissues, or only infiltrating the soft tissue.

8. Consistency when palpated.

- Consistency can be described as soft or compressible (eg, a lipoma or abscess), firm or indurated (eg, a fibroma or neoplasm), or hard (eg, torus or exostosis).
- Fluctuant is a term used to describe the wavelike motion sensed during bi-digital palpation of a lesion with non-rigid walls and that contains fluid.

9. Presence of pulsation.

- Palpation of a mass can disclose a rhythmic pulsation that is suggestive of a major vascular component. This sensation can be subtle and is especially important when dealing with intrabony lesions.
- The pulsation can be accompanied by a palpable vibration, called a thrill. If a thrill is palpated, auscultation of the area with a stethoscope might disclose a bruit, or audible murmur, in the area.
- Invasive procedures on lesions with thrills, bruits, or both should be avoided, and patients should be referred to specialists for treatment because life-endangering hemorrhage can result if surgical intervention (biopsy) is attempted.

10. Examination of regional lymph nodes.

- This examination should be accomplished before any biopsy procedure. Sometimes, lymphadenitis develops in the regional nodes after a surgical procedure such as biopsy, thus creating a subsequent diagnostic dilemma. Then, it can become difficult to differentiate reactive lymphadenitis as a surgical sequela from coincidental regional infection or inflammation from metastatic spread of the tumor in question. ■

PRE-BIOPSY MONITORING

Any undiagnosed or suspicious change in oral tissues that cannot be explained by localized trauma or other factors should be followed up in 7 to 14 days. If the lesion enlarges or expands, develops an altered appearance, or does not respond as expected to local therapy, a biopsy is usually indicated. Areas of leukoplakia can be problematic because up to 20% of those areas (and 100% of erythroplakia lesions) exhibit histological evidence of dysplasia or frank malignancy. High-risk areas of the mouth include the floor of the mouth, the lateral and ventral surfaces of the tongue, and the buccal and lower lip mucosa. Areas of redness or pebbling within areas of leukoplakia are especially troubling. Incisional biopsy specimens from at least 1 suspicious area are generally indicated. Table 2 list the lesion characteristics that raise suspicion of malignancy.

During subsequent examinations, the patient record should provide details on whether the observed lesion has improved or not improved and the dentist's plan for subsequent management (biopsy, or referral). (Fig. 1 and 2)■

TABLE 2. CHARACTERISTIC OF LESIONS THAT RAISE SUSPICION OF MALIGNANCY

- **Bleeding:** Lesions bleeds on gentle manipulation.
- **Duration:** Lesions persisted for more than 2 weeks
- **Erythroplasia:** Lesion is totally red or has a speckled red and white appearance.
- **Fixation:** Lesions attached to adjacent structures.
- **Growth rate:** Lesions exhibits rapid growth.
- **Induration:** Lesion and surrounding structure are firm to palpation.
- **Ulceration:** Lesion become ulcerated or presented as an ulcer.

CLINICAL PATHOLOGY

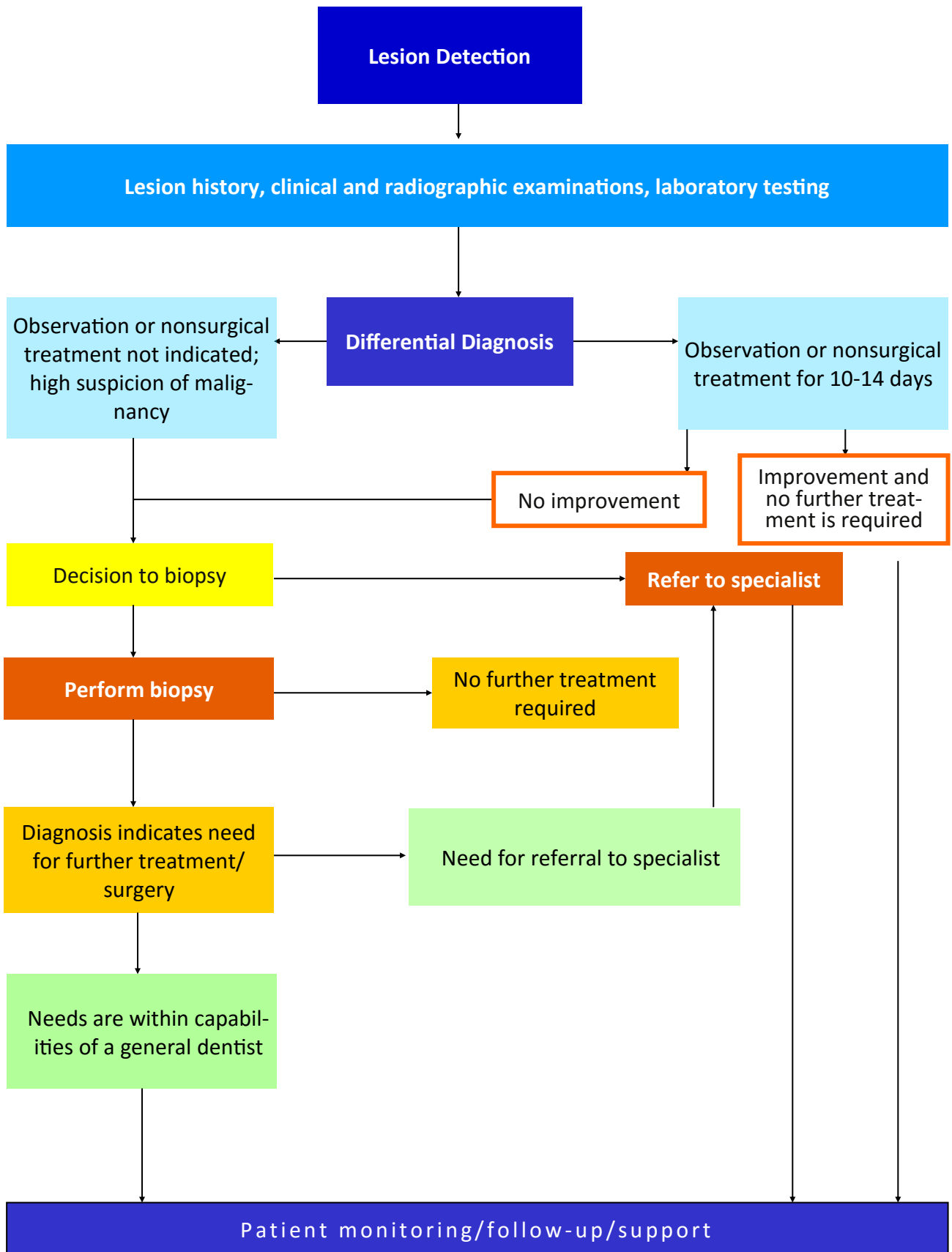


FIG.1. Decision tree diagram for managing suspicious lesions. Reprinted

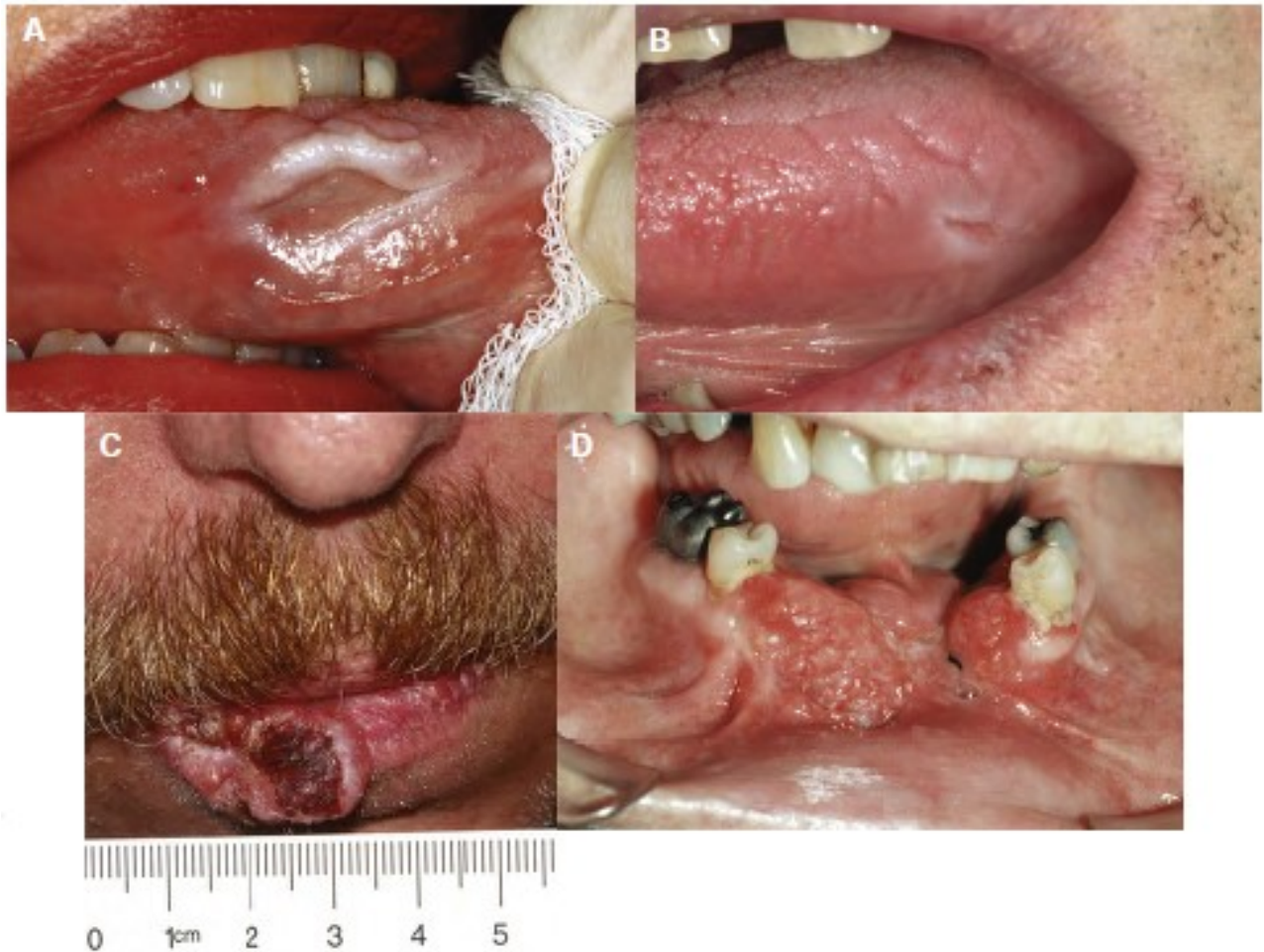

FIG. 2. Examples of lesions that should be considered for biopsy.

A, Ulcer on the lateral border of the tongue. In this case, it was a traumatic ulcer from biting. **B**, Another ulcer on the lateral border of the tongue. In this case, it was from a sharp edge of a fractured tooth cusp. **C**, Large ulcer of the lower lip, especially if in a patient with a history of smoking. This lesion was squamous cell carcinoma. **D**, Typical appearance of squamous cell carcinoma of the alveolar ridge. .

BASIC PRINCIPLES OF FOLLOW-UP AND REFERRAL

The ultimate responsibility for the detection of pathologic conditions (including oral cancer screening) rests with the dentist. Delegation of this duty is not permitted by law. The following should also be considered:

- If the dentist decides to refer the patient for a second opinion or specialty management, then the referral appointment ideally should be arranged before the patient leaves the office. If left to make the appointment themselves, many patients might fail to do so because of fear or denial.
- The arranged appointment should be followed with a letter or electronic message from the referring general dentist to the specialist, outlining the details of the case, the concerns, and the requested procedures.
- A copy of this correspondence should be placed in the patient record. Copies of the specialist's findings, recommendations, procedures, and biopsy findings also should be placed in the patient record. These formal exchanges provide precise documentation that prevents miscommunications between offices and can provide some protection if litigation is initiated later.
- The patient should be notified of the results, and if the results are unexpected or positive requiring further treatment, then the patient should be counseled in person by the dentist.

BIOPSY OR REFERRAL

Some dentists might be comfortable performing biopsy procedures on their patients, whereas others might refer their patients to a specialist. This is a personal choice and should take several points into consideration.

- **Health of the patient.** Greater number of medically compromised patients are now seen in the dental clinic. Such patients may need a special medical care during biopsy taking.. Patients can be referred to an oral and maxillofacial surgeon who is trained to manage patients with special medical needs so that the procedure is carried out as safely as possible.
- **Surgical difficulty.** The degree of surgical difficulty during taking the biopsy should be considered. Factors such as access, lighting, accessibility and the presence of nearby important anatomical structures should be considered. Each dentist should use his or her best judgment when deciding whether the biopsy is within the dentist's surgical abilities or if the patient would be better managed by a more experienced specialist.
- **Malignant potential.** The dentist who suspects that a lesion is malignant has two choices. The first is to perform a surgical biopsy after completion of comprehensive diagnostic workup or to refer the patient to a specialist who can provide definitive treatment if the lesion is

shown to be malignant. The latter choice usually represents better service to the patient as it save time, which is important. In addition, it is better for the referral specialist to evaluate the lesion before any surgical intervention has compromised its clinical features. Biopsy also can produce reactive lymph nodes that might be unrelated to the original lesion and even spread malignant tissue. Allowing the referral specialist to evaluate the patient before biopsy helps toward a more accurate diagnosis and aids in the formulation of a suitable treatment plan. ■

INSTRUMENTATION

INCISING TISSUE

Performing a biopsy of oral soft tissue usually involves incising the tissue with a scalpel. The scalpel is composed of a reusable handle and a disposable, sterile, sharp blade. Scalpels also are available as a single-use scalpel with a plastic handle and fixed blade. The most commonly used handle for oral surgery is the number 3 handle (Fig 3).

The tip of a scalpel handle is prepared to receive a variety of differently shaped scalpel blades to be inserted onto the slotted portion of the handle. The most commonly used scalpel blade for intraoral surgery is the number 15 blade (Fig 3)

Loading and unloading the scalpel

- The scalpel blade is carefully loaded onto the handle while holding the blade with a needle holder. This lessens the chance of injuring the fingers.
- The blade is held along the unsharpened edge, where it is reinforced with a small rib, and the handle is held so that the male portion points upward (Fig . 4,A).
- Then, the scalpel blade is slid slowly onto the handle along the grooves in the male portion until it clicks into position (Fig 4,B).
- The scalpel is unloaded similarly. The needle holder grasps the end away from the blade (Fig 4,C) and lifts it to disengage it from the male fitting portion.
- Then, the scalpel is slid off the handle, always away from the body (Fig 4,D).
- The used blade is immediately discarded into a specifically designed, rigid-sided sharps container.

Handling the scalpel

When using the scalpel to make an incision, the surgeon typically holds it in the pen grasp (Fig 5) to allow maximal control of the blade as the incision is made. Mobile tissue should be held firmly in place under some tension so that as the incision is made, the blade will incise and not just push away the mucosa. When incising depressible soft tissue, an instrument such as a retractor or a tissue forceps should be used to hold the tissue taut while incising.

Scalpel blades and blade-and-handle sets are designed for single-patient use. Blades dull easily after repeated strokes through keratinized tissue. Dull blades do not make clean, sharp incisions in soft tissue and therefore should be replaced before they become overly dull.



FIG. 3. Scalpels

(Upper) Scalpels come in two forms. One has a reusable handle and one-time use disposable blade (top) and the other has a blade/handle combination in which the entire blade/handle unit is discarded after one-time use (bottom). In both cases the blade or blade/handle unit must be placed into a red sharps disposable box.

(Lower) Scalpel blades come in various shapes and sizes. The most common blade used for oral surgery is the #15 blade, the right-most in this figure, followed by #12, 11 and 10.

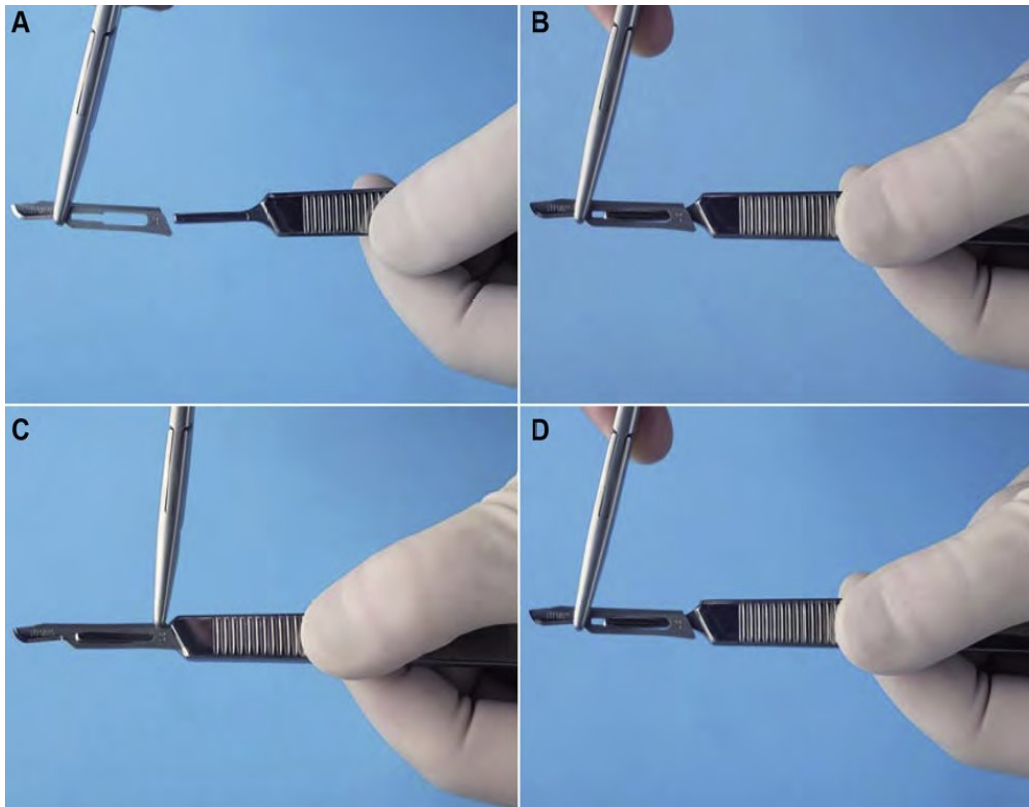


Fig. 4. Loading (upper) and unloading (lower) the scalpel.

CUTTING SOFT TISSUE (SCISSORS)

There are many types of scissors used while performing oral biopsies. They are designed for undermining and cutting soft tissue. Two major types of tissue scissors are used intraorally; iris scissors and Metzenbaum scissors (Fig 5). These scissors can have straight or curved blades. Iris scissors are small, sharply pointed, delicate tools used for fine work. Metzenbaum scissors are used for undermining soft tissue and for cutting. They can have sharp or blunt (rounded) tips. Tissue scissors such as iris or Metzenbaum scissors should not be used to cut sutures because the suture material will dull the edges of the blades and make them less effective and more traumatic when cutting tissue. Surgical scissors are held in the same manner as needle holders.

GRASPING TISSUE

Adson forceps can be useful when performing a biopsy. They can be used to grasp the tissue to stabilize the lesion while incising and then be used while suturing the resulting open wound. In some types of biopsies, forceps with locking handles and teeth that will grip the tissue firmly are necessary. In this situation, the Allis tissue forceps are used (Fig 6). The locking handle allows the forceps to be placed in the proper position and then to be held by an assistant to provide the necessary tension for proper dissection of the tissue. The Allis forceps should never be used on tissue that is to be left in the mouth because they cause a relatively large amount of tissue destruction as a result of crushing injury. ■

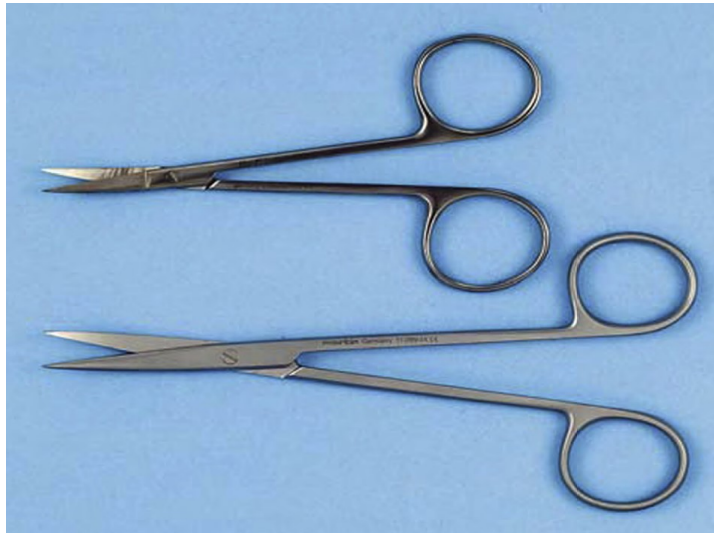

FIG. 5. Soft tissue scissors;
Iris (upper) and Metzenbaum (lower) scissors

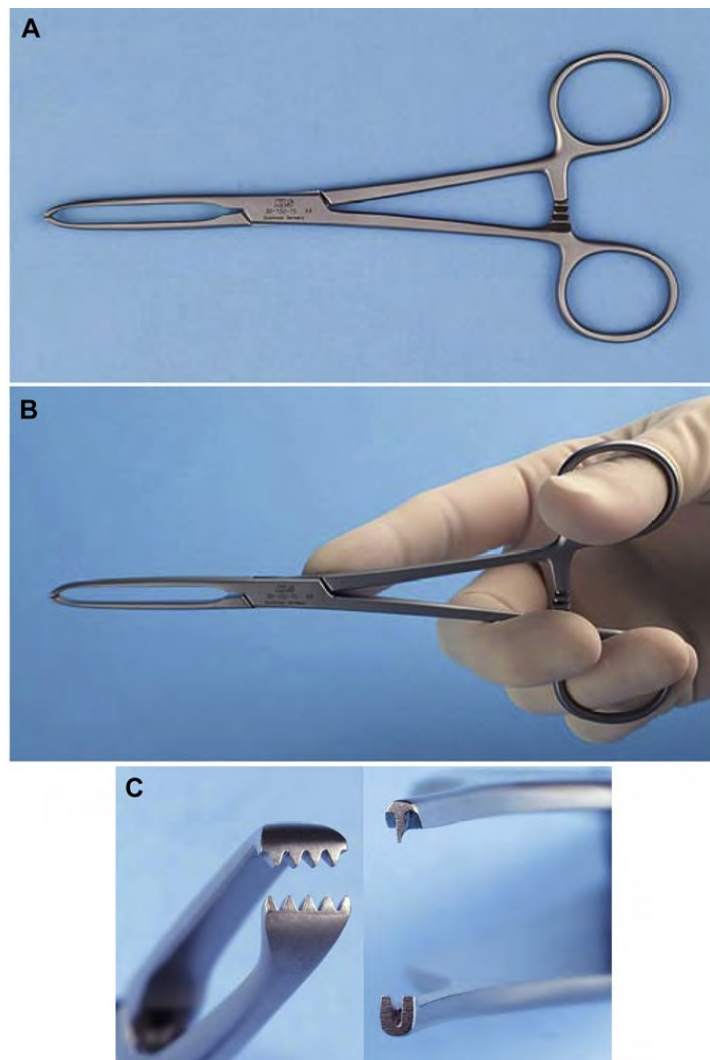


Fig 6. Grasping the tissues

A, Allis tissue forceps are useful for grasping and holding tissue that will be excised. B, Allis forceps are held in the same fashion as the needle holder. C, Comparison of Adson beaks (right) with Allis beaks (left) shows the differences in their designs.

SOFT TISSUE BIOPSY TECHNIQUES

Biopsy of oral soft tissues is a useful competency for a general dentist to possess. When performed properly, most biopsies are straight forward procedures that can be readily performed in the dental office using local anesthesia and minimal instrumentation. The only variables of the technique relate to areas of anatomic risk or limitations imposed by the size and type of lesion.

ANESTHESIA

Block local anesthesia techniques are preferred over infiltration, whenever possible, so that the anesthetic solution is not inadvertently incorporated in the surgical specimen. Infiltration anesthesia can cause distortion of the cellular architecture of the specimen and make pathologic diagnosis more difficult, if not impossible. Peripheral infiltration of local anesthetic with a vasoconstrictor is often helpful, injecting at least 1 cm away from the lesion's perimeter to prevent distortion of the lesion itself.

INCISIONAL BIOPSY

An incisional biopsy is a procedure that removes only a portion of the lesion. If the lesion is large or exhibits differing characteristics in different locations, then more than 1 area of the lesion might require sampling. Incisional biopsies are used when:

- The lesion is large (>1 cm in diameter), or located in a hazardous location,
- A definitive histopathologic diagnosis (eg, for suspected malignancy) is desired before a complex removal or other treatment.

The following should be considered during taking an incisional biopsy:

- The incisional biopsy is generally excised as a wedge of tissues that intentionally includes normal- and abnormal appearing tissues in the sample.
- The only exception to this approach is when a malignant lesion is strongly suspected. In that circumstance, including normal- appearing tissue in the specimen could spread malignant cells. (Fig. 7)
- Avoid the central area of the lesion which is often necrotic and of little diagnostic values.
- Care must be taken to include an adequate depth of tissue, so that cellular features from the base of the lesion are included.
- In general, it is better to take a narrow, deep specimen rather than a broad, shallow one. .

EXCISIONAL BIOPSY

An excisional biopsy consists of the removal of a lesion in its entirety, to include a 2- to 3-mm perimeter of normal tissue around the lesion. An additional 2 to 3 mm of tissue might be required for specimens suspected of being malignant, including some pigmented lesions and lesions already diagnosed as having dysplastic or malignant cells. (Fig. 8)

Complete excision often constitutes definitive treatment of the lesion biopsied. Excisional biopsy also is reserved for smaller lesions (<1 cm in diameter), taking care to avoid adjacent nerves or blood vessels unless they are thought to be a part of the lesion or the lesion has been determined to be a malignancy. ■

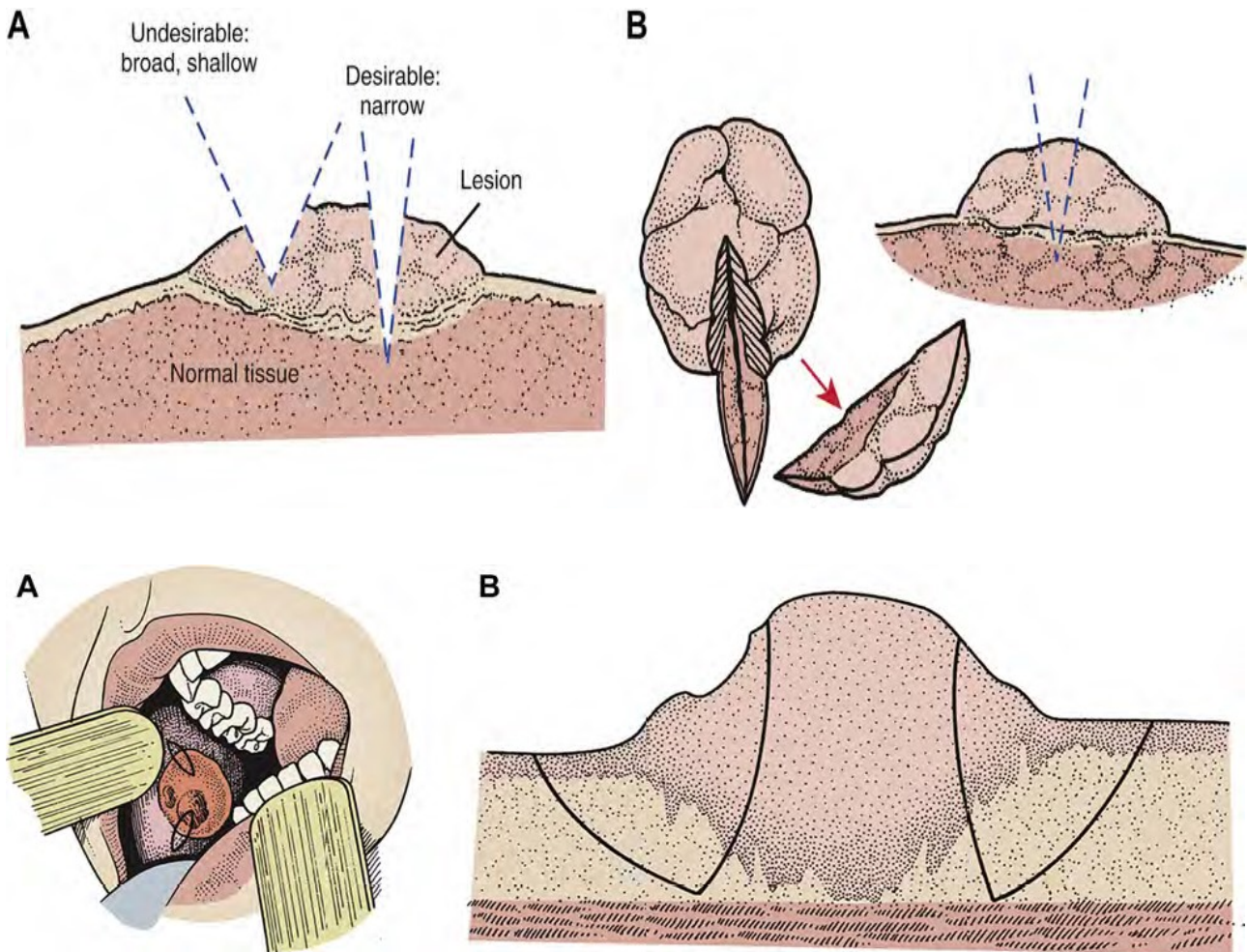


FIG.7. Principles of incisional biopsy.

(Upper) A, Obtaining a deep specimen, rather than a broad and shallow specimen, when incisional biopsy is performed. If malignant cells are present only at the base of the lesion, then a broad and shallow biopsy might not obtain these diagnostic cells. B, Obtaining incisional biopsy at the margin of the soft tissue lesion. The junction of the lesion with normal tissue frequently provides the pathologist with more diagnostic information than a biopsy specimen taken only from the center of the lesion. This is particularly important when a biopsy of an ulcer is performed.

(Lower) A, Frequently, one area of a lesion appears histologically different from another. Therefore, it is often desirable to obtain more than 1 incisional biopsy to detect whether the characteristics of the lesion differ from one area to another. B, When obtaining a biopsy on buccal or labial mucosa, the incision is usually carried to the depth of the musculature.

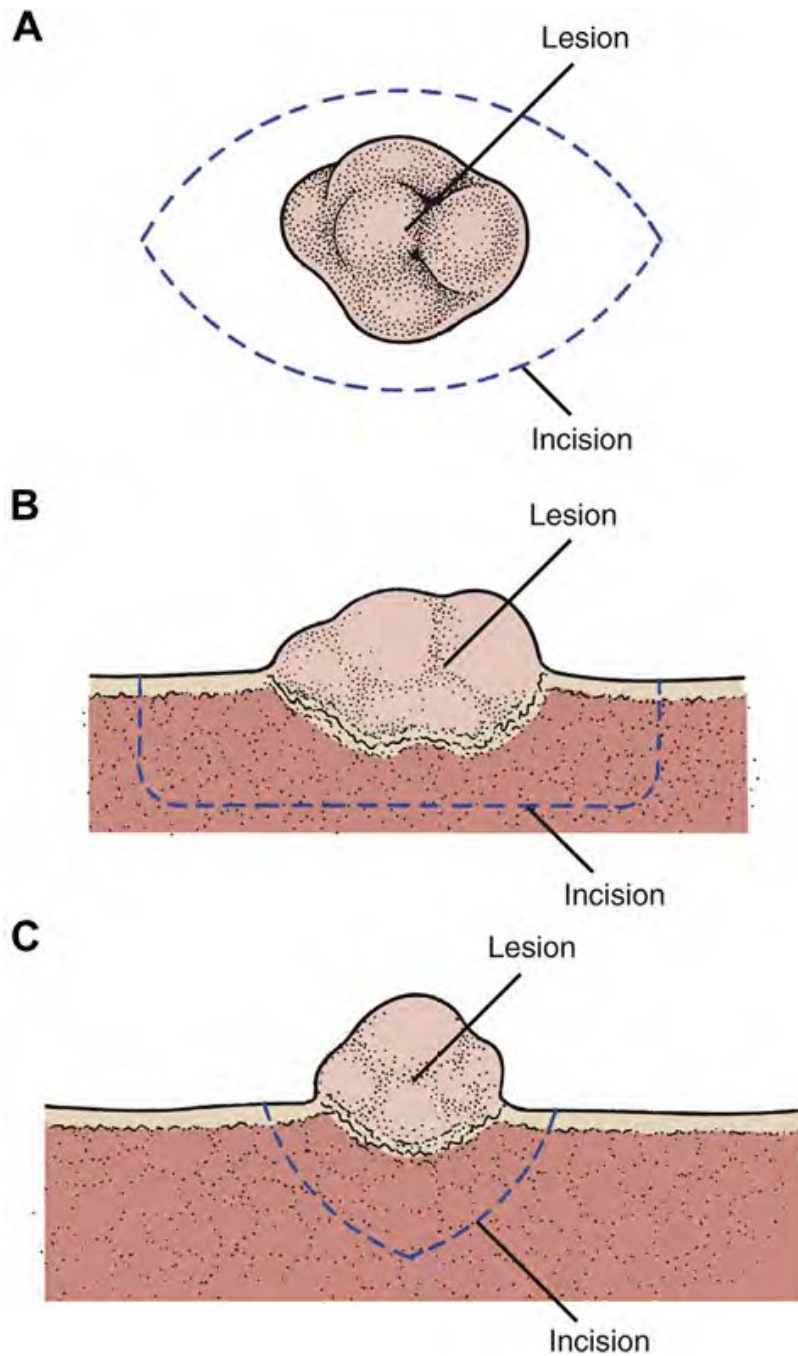


FIG.8. Excisional biopsy of soft tissue lesion.

A, Surface view. An elliptical incision is made around the lesion, at least 3 mm away from the lesion. B, Side view. The incision is made deep enough to remove the lesion completely. C, End view. Incisions are made convergent to the depth of the wound. An excision performed this way facilitates closure.

For other methods of tissues screening and examination, refer to the outline presentation on page 30.

TISSUE STABILIZATION

Oral soft tissue biopsies frequently involve mobile surfaces and structures (e.g., lip, cheek, and tongue). Accurate surgical incisions can be placed with greater ease when the involved tissues are first stabilized. This can be accomplished by any of several methods. (Fig. 9 and 10)

- The surgical assistant can grasp the lip on both sides of the biopsy site with his or her fingers, which also retracts and immobilizes the lip. This also can help decrease bleeding by compressing labial blood vessels and their tributaries.
- Different retractors are available that can perform the same function.
- When used, retraction sutures should be placed deeply into the tissues, away from the planned biopsy site, so that they can function without pulling through or damaging the tissues.

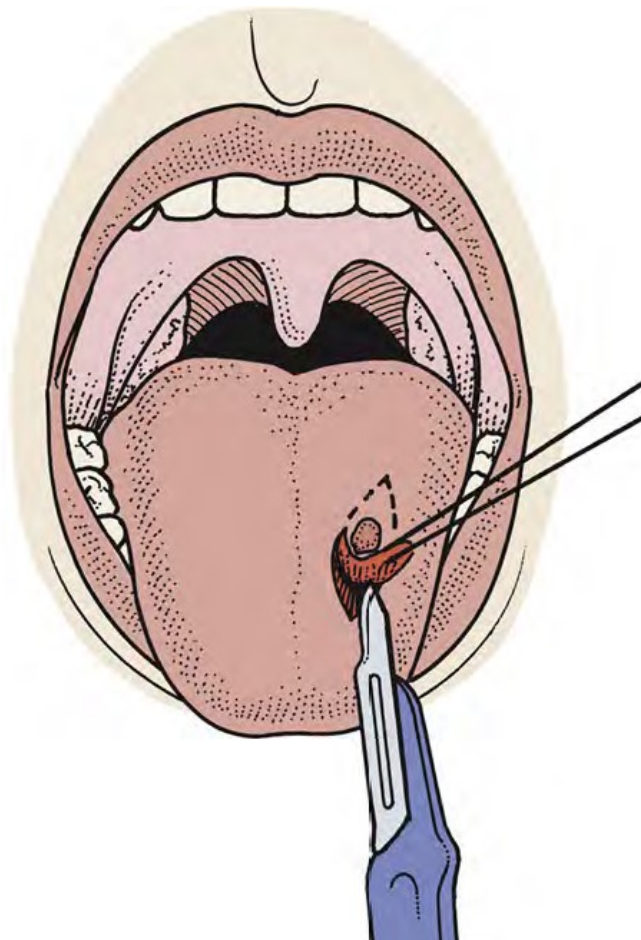
HEMOSTASIS

FIG 9. Traction suture

Use of traction suture placed through the specimen. While the lesion is incised, a traction suture is used to lift the specimen from the wound bed. Then, the suture can be tied and left attached to the lesion to identify the orientation of the specimen

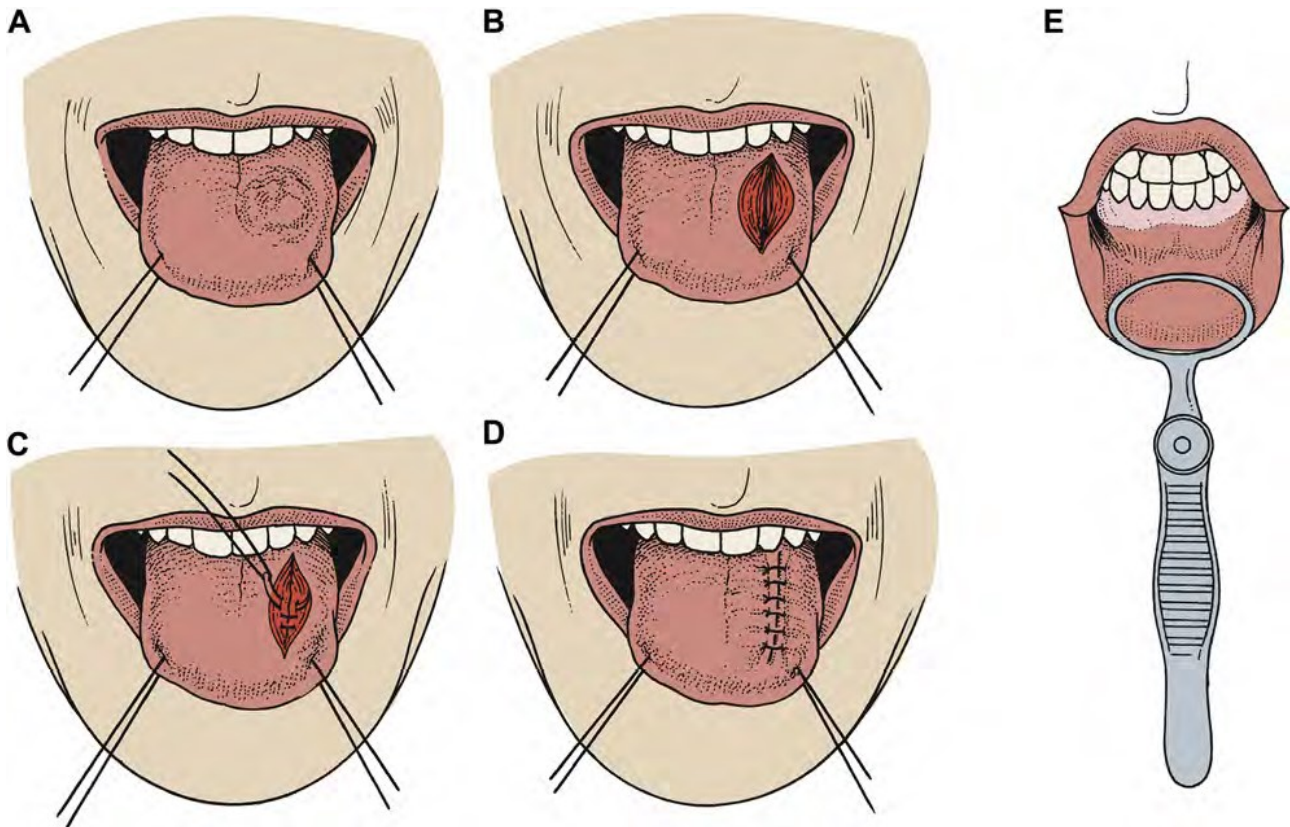


Fig.10. Stabilization of tongue for biopsy.

A, Stabilization of tissue with traction sutures. Two silk sutures are used to stabilize the tongue before excisional biopsy. They are placed through the substance of the tongue (mucosa and muscle) to prevent pulling through tissue. B, The lesion is removed after an elliptical incision has been made around it. C, Resorbable sutures are placed to approximate muscle. D, The mucosa is closed. E, Alternative means of stabilization of tissue using a Chalazion-type device.

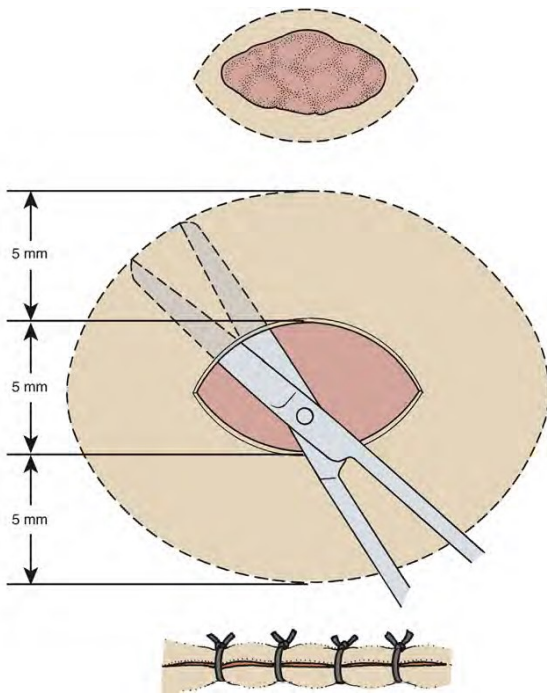


FIG. 11. The principles used in closing an elliptical biopsy wound.

The mucosa should be undermined bluntly with scissors to the width of the original ellipse in each direction. Scissors are inserted under mucosa tissue while closed and then opened to spread tissues, undermining the mucosa in that area. This is repeated around the periphery of the wound. This allows approximation of wound margins without tension.

The use of a suction device for keeping the surgical field free of blood during the procedure should be minimized as much as possible, especially high-volume suction devices. The assistant can usually use gauze sponges to blot the site during the procedure. Suctioning can increase not only bleeding but also the risk of the biopsy tissue sample being accidentally aspirated into the suction. If suction is needed, it is helpful to place gauze over the end of the suction tip to serve as a filter.

WOUND CLOSURE

After removal of the tissue sample, primary closure of the wound is desirable and usually possible. The wound left after a larger biopsy often will not close without tension on the wound edges. Undermining of adjacent surface tissue is used to help decrease the tension on wound edges during closure. The following should be considered during wound closure:

- Mucosa is undermined by using a spreading action of the tips of small scissors to separate the mucosal from the submucosal tissues (Fig. 11). The submucosal layer is largely loose connective tissue that is easily dissected free from the overlying mucosa without sharp incision or snipping.
- This permits closure of the mucosa as a separate layer without regard to closure of the deeper layers.
- The extent to which this undermining is carried out is determined by the size of the wound and the anatomic location.
- Suture materials of choice are generally black silk or a resorbable material.
- Biopsy wounds on the dorsum or lateral border of the tongue require deeply placed sutures at close intervals to counteract inherent muscle movements and maintain closure. (Figs 12)■

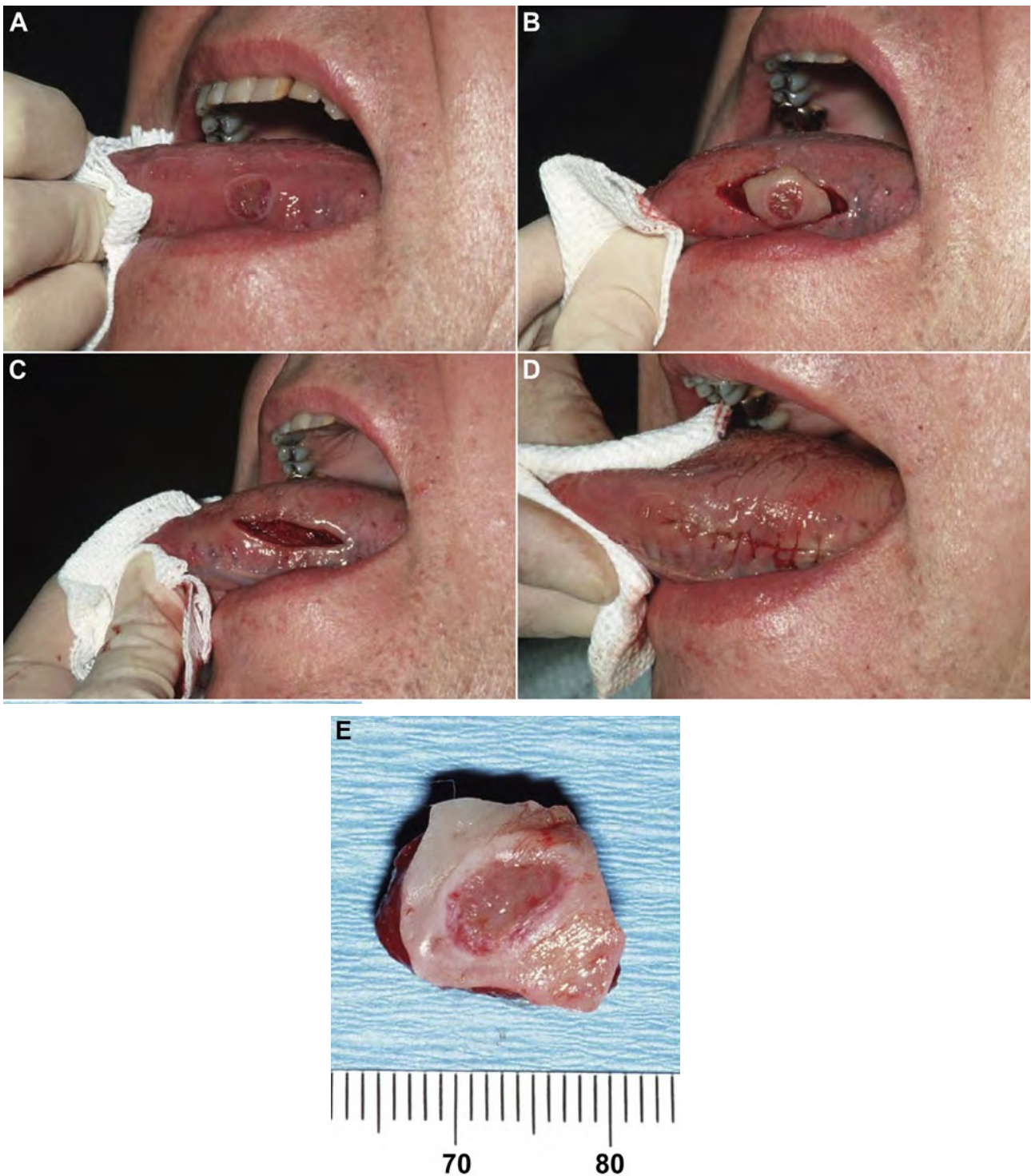


FIG.12. Excisional biopsy of a tongue ulcer.

A, Ulcer on the lateral border of the tongue. B, Elliptical incisions are made around the lesion, with 2 to-3 mm of normal tissue included. C, Appearance after the specimen has been removed and the muscle has been sutured. Note that the deep sutures have made an almost linear closure of the mucosa possible. D, Appearance after mucosal closure. E, Specimen.

HANDLING THE SPECIMEN

Any tissue specimen must be maintained in a condition that is optimal for preserving the histological and structural architecture of the cells of the lesion. Specimens that have been crushed, frozen, desiccated, burned, or otherwise compromised might not be microscopically diagnostic. The following should be considered:

- The removed tissue sample should not be wrapped in gauze (wet or dry) because it is at risk of getting thrown out accidentally with the gauze.
- The specimen should not be set on paper or linen drapes and allowed to dry out while the surgery is being completed.
- The specimen should be placed immediately in a glass or plastic container that contains a quantity of 10% formalin solution (4% formaldehyde) that is at least 20 times the volume of the specimen itself and that can be capped.
- The specimen must be totally immersed in the preservative solution at all times, even if the container is tilted sideways during transport.
- Before turning attention to wound closure, the dentist should ensure that the tissue sample does not adhere to the container wall above the level of the formalin.
- If the specimen is mailed to the pathologist, then it must be labeled with a biohazard label approved by the Occupational Safety and Health Administration. (Fig. 13 and 14)



FIG. 13. Handling the specimen.

A specimen being dropped into a biopsy bottle filled with formalin. Do not re-enter the wound with the forceps unless they are first rinsed free of the fixative solution.

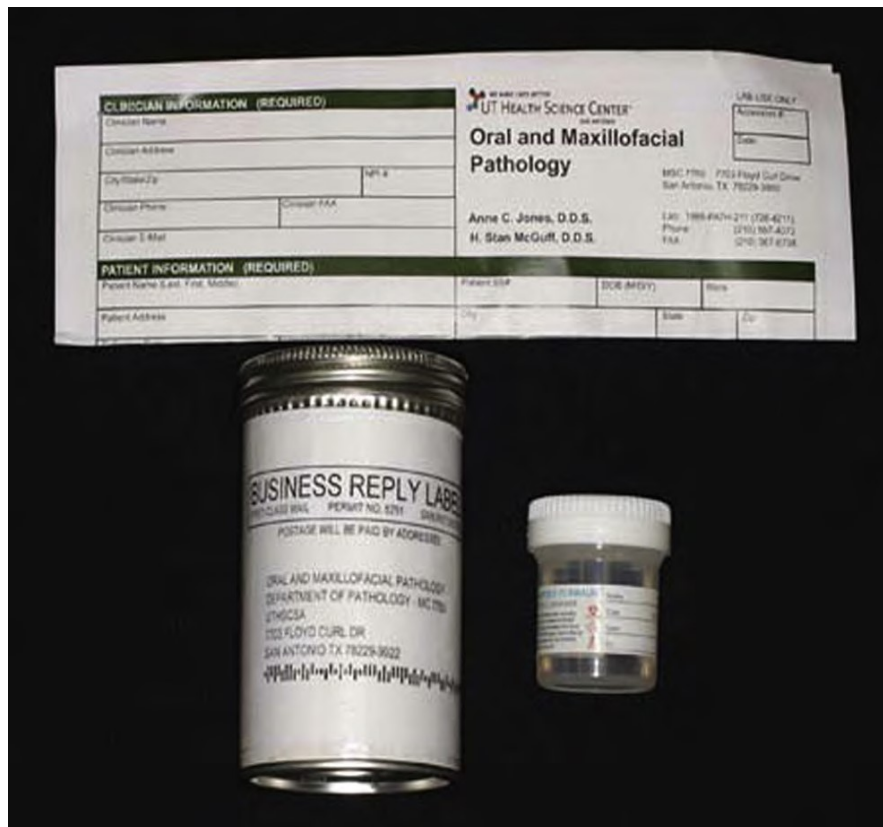


FIG. 14. Typical biopsy kit that is available from pathology laboratories.

The kit includes a specimen bottle containing formalin, a biopsy requisition form onto which information about the patient and specimen is documented, and a mailer to send the specimen back to the laboratory

TAGGING OF SPECIMENS

If dysplasia or malignancy is suspected, it is helpful to the pathologist if the surgeon “tags” one of the margins of a specimen with a loosely tied suture to orient the anatomic alignment of the specimen. The orientation and location of the marker suture should be illustrated, documented, or both on the oral and maxillofacial pathology service’s submission form (Fig. 15). Suture tagging also can be used to identify multiple specimens from one lesion when accompanied by a drawing that delineates from which area each specimen was removed and the orientation of each specimen. The first specimen receives 1 tagging suture and the second receives 2, and so on, for all other specimens. However, each specimen should be submitted in its own container.

SUBMISSION OF SPECIMENS

Every dental office should prearrange a relationship with a local or regional oral and maxillofacial pathology examination service where specimens can be submitted. In general, it is preferable to have odontogenic tissues submitted to an oral and maxillofacial pathologist, whenever possible. Highly competent, general (medical) pathologists might not be familiar with the subtleties of odontogenic cysts and tumors, which occasionally can result in incorrect diagnoses and treatment.

Surgical Pathology Requisition Form
Dental Associates Oral and Maxillofacial Pathology Biopsy Service

Date of Surgery: _____ Date Specimen Received: _____

Patient Name: _____ Dental Record # _____
Last First Middle

Patient Address: _____
_____ Phone # _____

Patient Age: _____ DOB: _____ Gender: M or F
Circle one

Referring Clinician: _____ Dental Lic# _____ NP# _____

Practice Name and Address: _____

Practice Phone: _____ Fax: _____ Email Address: _____

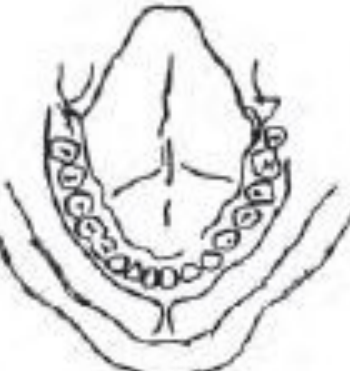
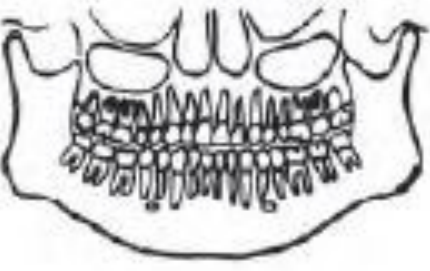
Clinical Description (including size): _____

Clinical History: _____

Clinical Impression: _____ Previous Biopsy: Y or N (# _____)

Procedure: _____ Excisional Biopsy _____ Incisional Biopsy Other _____

Location of Lesion (please draw in anatomic location)

R
L
R
L
R
L

Radiograph Y/N or clinical photo sent Y/N

***Record Insurance Information on the back of this form.**

FIG 15. Example of a biopsy requisition form.

Such forms vary from one laboratory to the next. Illustrations of oral cavity and perioral areas that are useful when indicating the size and location of oral lesions are often on the datasheet as shown here.

BIOPSY SUBMISSION FORM

Each pathology laboratory has a form unique to its facility for use in submitting specimens for examination (Fig 15). As noted earlier, the specimen container must be labeled and identified with the demographic data of the patient and the name and address of the submitting dentist in the event it gets separated from the submission form, transporting container, or both. Most forms are structured to gather supporting information and data, which generally include:

- Demographic data about the patient; name and contact information for the submitting dentist; medical and family history of the patient.
- Clinical description of the lesion, specimen, or both; and presumptive clinical differential diagnoses. The dentist must take the time to provide as much information on the submission form as possible to aid the pathologist. Insufficient information, incomplete data, or important omitted historical notes often lead to wasted time and inaccurate diagnoses.

A negative (benign) pathology report should never be taken as a final assessment, and the dentist should not be lulled into a false sense of security when one is received. If the clinical behavior of a lesion suggests that it is not benign, a second biopsy of the area should be considered. Moreover, a nondiagnostic or unrepresentative area of the lesion might have been sampled, and the areas of pathologic cellular changes might not have been included in the specimen(s). Errors in microscopic diagnosis also occur, especially if odontogenic tissues are examined by general pathologists who might be unfamiliar with the nuances of oral and odontogenic lesions. It is not inappropriate in such cases to ask for a second pathology opinion from an oral and maxillofacial pathologist before contemplating ablative or disfiguring surgery. General dentists who submit biopsies also must be conversant with the terminology used in reports to fully grasp the meaning of the microscopic diagnosis and the course of treatment or follow-up that is appropriate for that diagnosis. If any uncertainty about the contents of the report exists, then the dentist should seek clarifications from the pathologist. ■

ORAL BIOPSY

WHY?

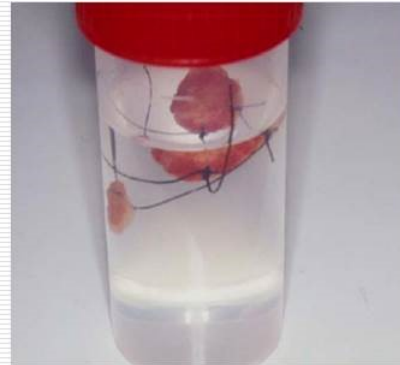WHEN

HOW

PRESENTATION - OUTLINE SUMMARY

Definition

- Biopsy is a surgical procedure to obtain tissue from living organism for histopathologic examination, usually to perform diagnosis. It is the most diagnostic examination available



Before any biopsy it is the data collected that allows formulation of a differential diagnosis. Looking for a definitive diagnosis is the aim of biopsy

Oral Biopsy ... Why

□ **The aim of biopsy is to :**

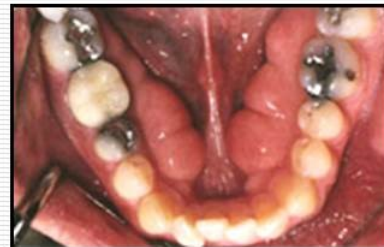- Define a lesion on the basis of its histopathological aspect
 - To establish a prognosis in malignant and premalignant lesions
 - Facilitate the prescription of specific treatment
 - Act as a document with medical-legal value
-

Oral Biopsy ... Why

- For diagnostic confirmation of
 - Suspected **malignant** lesions,
 - **Precancerous** lesions
 - Chronic **ulcerations** of unknown cause
 - Apparently **inflammatory lesions** that do not improve within two weeks of removal of local irritants
-

Oral Biopsy ... When Not Needed

- Normal structures;
 - Irritative or traumatic lesions that respond to the removal of the local irritant;
 - Inflammatory or infections lesions that respond to specific local treatments
 - Lesions” of long duration with minor clinical change.
 - Torus palatinus and mandibularis
-



Oral Biopsy ... When Not Needed

- ❑ Pulsating lesions (those of vascular nature)
 - ❑ Pigmented lesions (melanoma)
 - Cutting through the lesion may initiate malignant transformation
 - ❑ **Major salivary glands lesions**
 - Cutting through usually result in salivary fistula
-

Oral Cancer

- ❑ Is the **sixth most common cancer**, accounts for nearly **3.6** percent of all cancers diagnosed
 - ❑ Increase in oral cancer among young adults
 - ❑ Increase in the incidence of tongue cancer cases nearly **5-folds** during the last 30 years
 - ❑ Incidence and survival rate
 - 30,000 new cases diagnosed yearly
 - 8,000 deaths each year
 - 5 year survival rate: 50%
-

Early Detection ... Saves Lives

- 5-year survival
 - for localized lesions is **76%**
 - 5-year survival
 - for metastatic lesions is **19%**
-

Dentist Role

The key for reduction of death due to oral cancer is early detection, and **dentist** can play an important role !

- Thorough oral examinations, and detection of the early lesions
 - Biopsy and histological evaluation of the lesion
-

Oral Biopsy ... General Principles

- Before the procedure is undertaken, the characteristics of the lesion should be described in the patient's clinical records together with
 - Possible differential diagnosis.
 - The patient should receive information on the reasons why it is performed.
-

Tissue Examination Methods

□ *Screening*

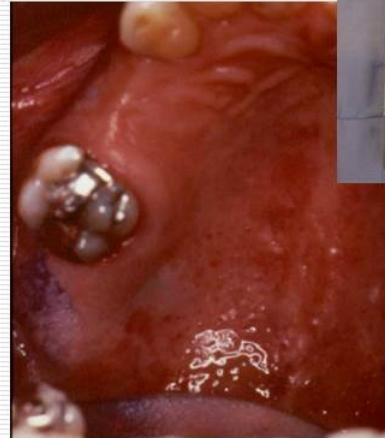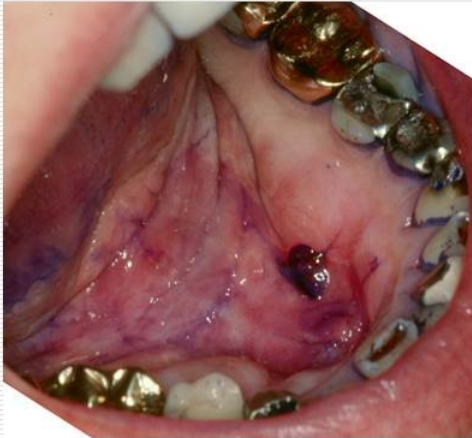- Toluidine Blue
- Oral Brush biopsy
- Exfoliative cytology

□ *Sampling*

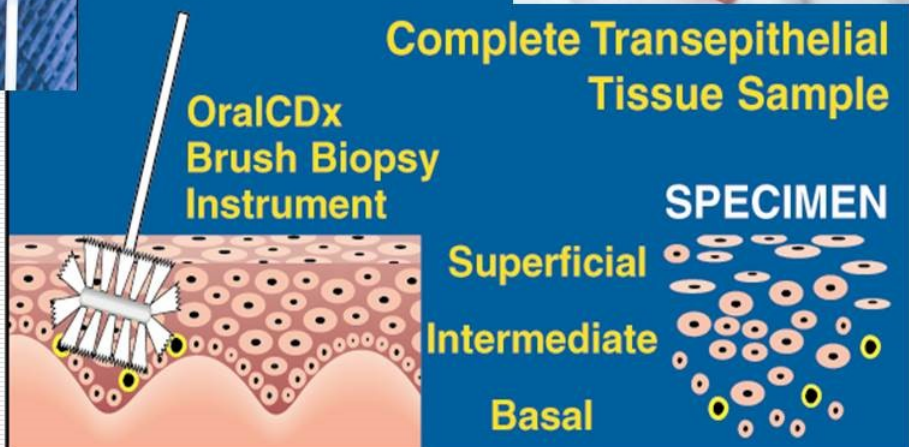
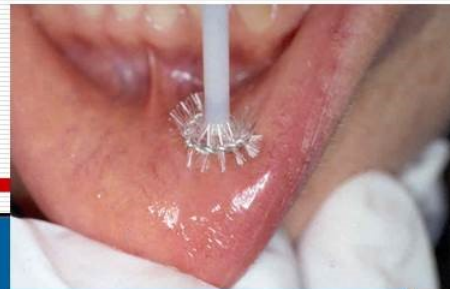- Fine needle aspiration biopsy
 - Incisional biopsy
 - Excisional biopsy
 - Drill biopsy
 - Frozen sections
-

Toluidine Blue

- *Displays affinity for areas of dysplasia, malignancy and high cell turn over*



Brush Biopsy



Brush Biopsy

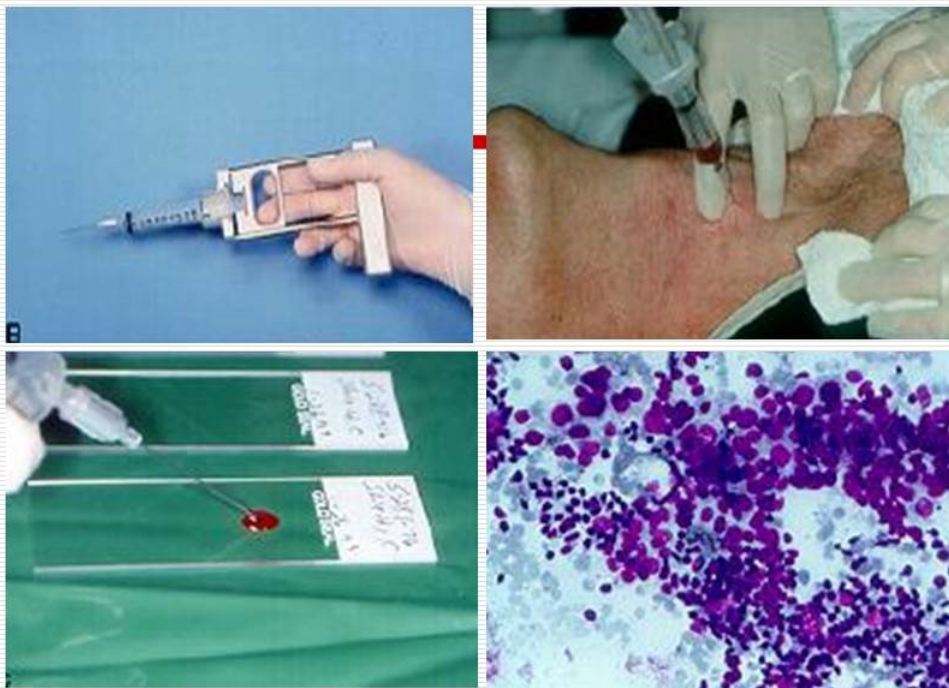
- ❑ Think of this technique as a screening tool
 - ❑ This kit helps you decide which lesions need to undergo conventional biopsy
 - ❑ If a lesion is highly suspicious, skip this option and go right to the incisional/excisional biopsy
-

Exfoliative Cytology

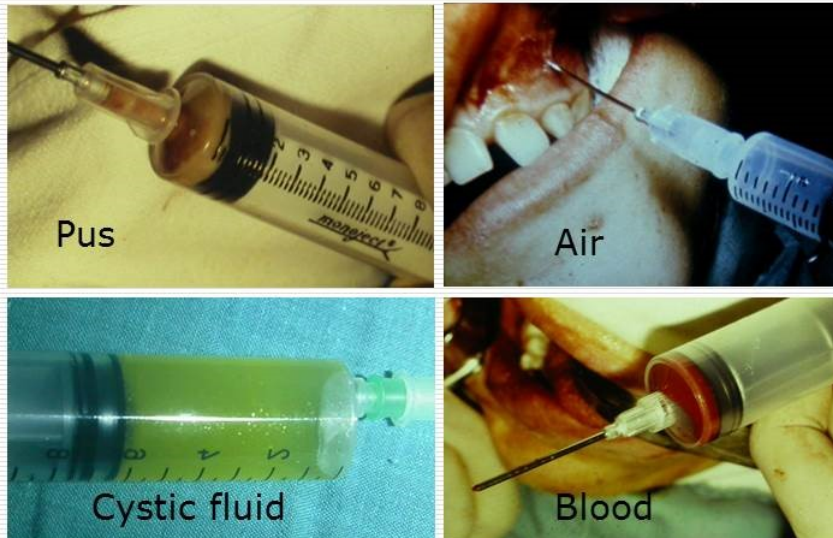
- ❑ Should not be used as a substitute for a conventional biopsy because of the false-negative results –
 - ❑ ***True Positive, False Negative***
 - ❑ The technique consists of scrapping the lesion with a tongue blade or spatula and spreading the scrapping over a glass slide, which is fixed immediately in 95% ethyl alcohol, then allow to dry in air and examined
-

Fine Needle Aspiration Biopsy

- ❑ Aspiration of cells or fluid for subsequent analysis
- ❑ Technique consists of repeatedly passing a needle, under negative pressure, through a lesion to collect cells
- ❑ Fluid aspirated from a lesion can also be sampled
- ❑ Generally requires analysis by a cytopathologist
- ❑ Indications:
 - Salivary gland masses
 - Neck masses
 - Aspiration of jaw cysts or other lesions



Aspiration Biopsy



Aspiration Biopsy

- When applied to jaw lesions:
 - ***Air*** suggestive of traumatic bone cyst
 - ***Straw coloured fluid***: cyst
 - ***Pus*** : inflammatory or infectious process
 - ***Blood, under high pressure***: suggestive of high flow vascular lesion.
 - ***Blood, under low pressure***: aneurismal bone cysts, central giant cell granulomas
-

Types of Biopsy

□ **Area of surgical removal:**

- **Incisional biopsy:** consists of the removal of a representative sample of the lesion and normal adjacent tissue in order to make a definitive diagnosis before treatment
 - **Excisional biopsy:** is aimed at the complete surgical removal of the lesion for diagnostic and therapeutic purposes
-

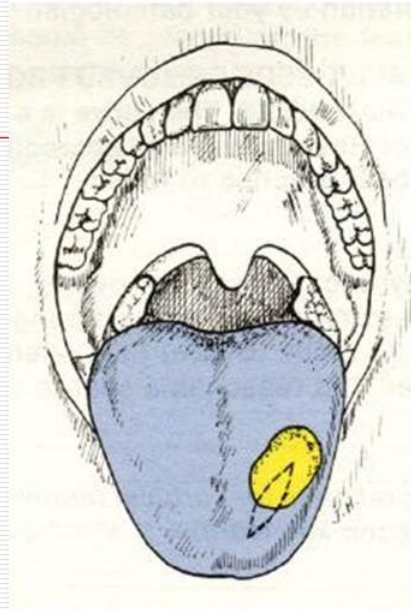
□ **Timing of the biopsy:**

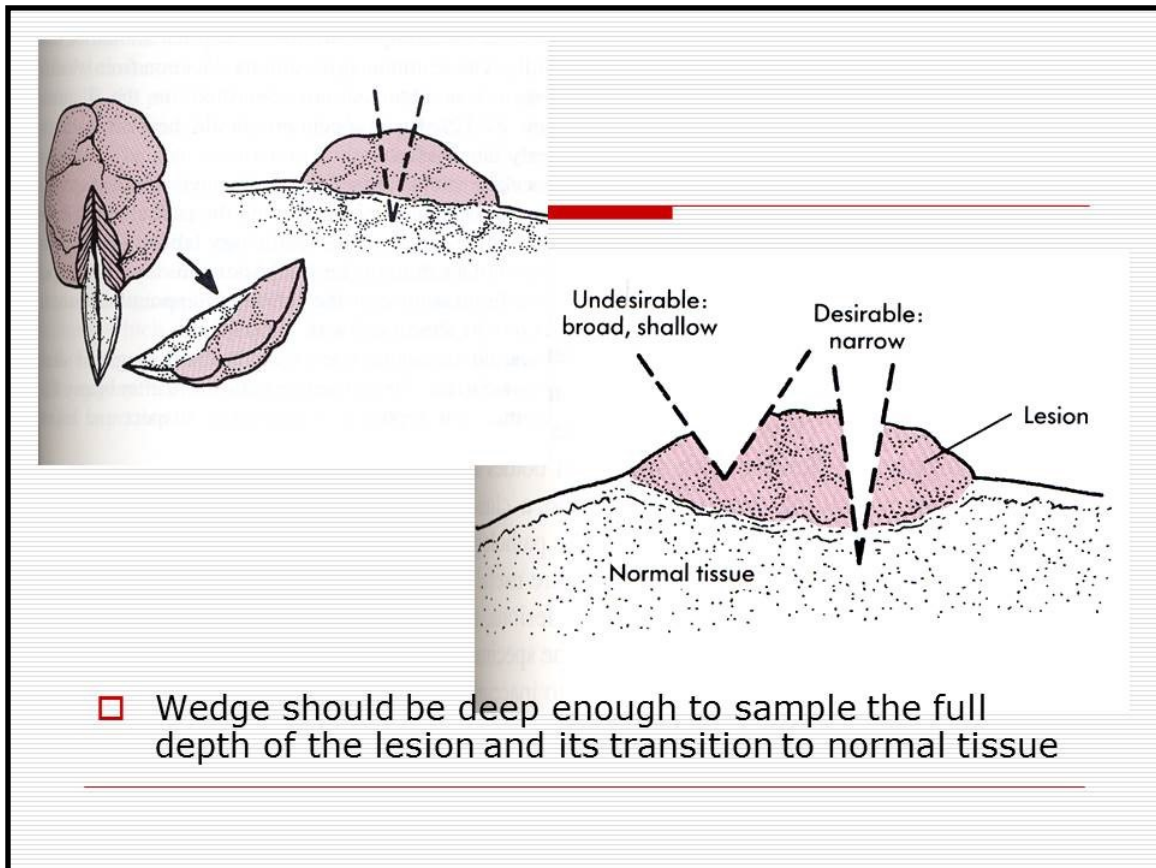
- Pre-operative
 - Intra-operative
 - Post-operative when aimed at checking the efficiency of a treatment
-

Incisional Biopsy

- ❑ Technique simple, only a portion of the lesion is removed
 - ❑ ***Indications:***
 - Large lesions with more than 1cm in diameter
 - Hazardous location
 - Malignancy suspected
-

-
- ❑ Biopsy of a wedge of representative tissue
 - ❑ Several regions may be sampled
 - ❑ Avoid necrotic tissue
 - ❑ Areas of tissue transition can be useful, such as the margin of the lesion
-

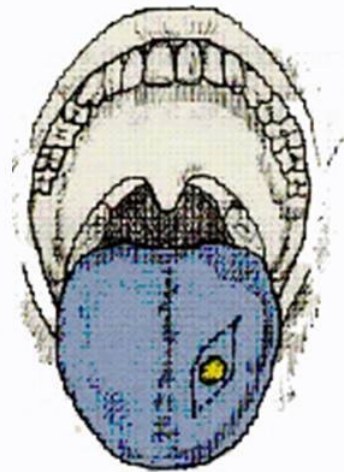
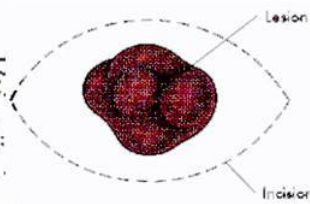
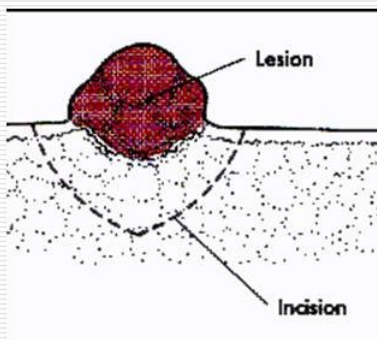




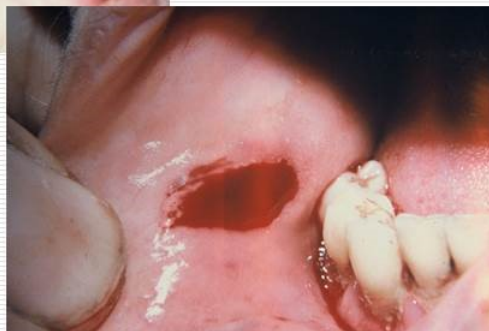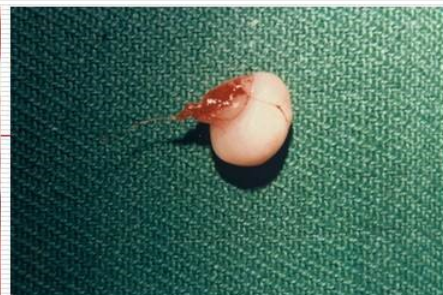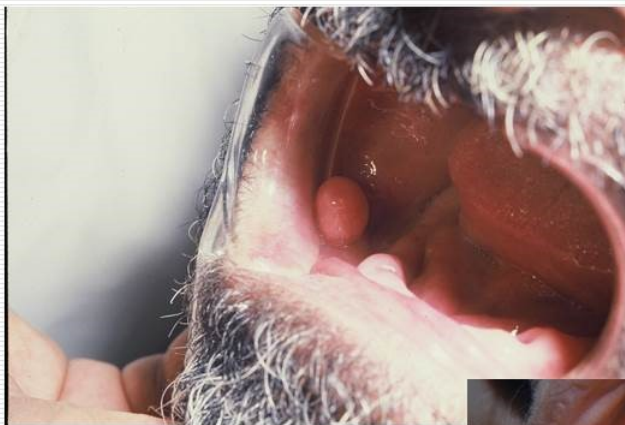Excisional Biopsy

- ❑ Removes the entire lesion at the time of tissue sampling
- ❑ A margin of normal tissue is generally included
- ❑ Offers the advantage of definitive treatment at the time of diagnosis
- ❑ **Indications:**
 - Smaller lesions, < 1cm
 - Pigmented and small vascular lesions
 - Benign lesions

Principle: lesion and 2-3mm margin of normal tissue is excised



- Elliptical incision is carried-out allowing for a narrow rim of normal peripheral tissue
- Beveling your incisions to a narrow "V" base facilitates wound closure



REFERENCES AND FURTHER READING

1. Williams PM, Poh CF, Hovan AJ, Ng S, Rosin MP. Evaluation of a suspicious oral mucosal lesion. *J Can Dent Assoc* 2008; 74(3):275–80.
2. Ellis E III. Principles of differential diagnosis and biopsy. In: Peterson L, Ellis E III, Hupp JR, Tucker MR, editors. *Contemporary oral and maxillofacial surgery*. St. Louis: Mosby; 1998. p. 515–32.
3. Moule I, Parsons PA, Irvine GH. Avoiding artefacts in oral biopsies: the punch biopsy versus the incisional biopsy. *Br J Oral Maxillofac Surg* 1995; 33(4):244–7.
4. Rosin MP, Poh CF, Elwood JM, Williams PM, Gallagher R, MacAulay C, and others. New hope for an oral cancer solution: together we can make a difference. *J Can Dent Assoc* 2008; 74(3):261–6.
5. Gale N, Pilch BZ, Sidransky D. Epithelial precursor lesions. In: Barnes L, Eveson J, Reichart P, Sidransky D, editors. *World Health Organization classification of tumours: pathology and genetics of tumours of the head and neck*. Lyon: IARC Press; 2005. p. 143.
6. Lumerman H, Freedman P, Kerpel S. Oral epithelial dysplasia and the development of invasive squamous cell carcinoma. *Oral Surg Oral Med Oral Pathol Oral Radiol Endod* 1995; 79(3):321–9.
7. The Early Detection of Oral Cancer Working Group. Guideline for the early detection of oral cancer in British Columbia 2008. BC Oral Cancer Prevention Program of the BC Cancer Agency. March 2008. Available: www.cdsbc.org/pdf/OC_Guideline_Final_2008.pdf
8. Guide to suturing, with sections on diagnosing oral lesions and post-operative medication, *Journal of Oral and Maxillofacial Surgery*, Editor James R. Hipp, August 2015, Volume 73 • Supplement 1, www.joms.org
9. Amparo Mota-Ramírez, Francisco Javier Silvestre, Juan Manuel Simó: Oral biopsy in dental practice *Med Oral Patol Oral Cir Bucal*. 2007 Nov 1;12(7):E504-10
10. Biopsy an essential diagnostic tool. *Dent. Today* 1998;17,83-85
11. Scully C, Felix D H: Update for the dental practitioners. Oral cancer. *Br Dent J* 2006; 14:13-8.
12. Pía López Jornet, Antonio Velandrino Nicolás, Yolanda Martínez Beneyto, Mercedes Fernández Soria: Attitude towards oral biopsy among general dentists in Murcia. *Med Oral Patol Oral Cir Bucal* 2007;12:E116-21
13. R. J. Oliver, P. Sloan, M. N. Pemberton: Oral biopsies: methods and applications. *British dental journal* 2004;196:329
14. How competent our graduates feel. *J. dent. Edu.* 1998;62: 307-313.
15. Biopsy issues & procedures. *Dent. Today* 1995;14, 50-55
16. Diamanti N, Duxbury AJ, Ariyaratnam S, Macfarlane TV: Attitudes to biopsy procedures in general dental practice. *Br Dent J* 2002; 192: 588-92.
17. Biopsy an essential diagnostic tool. *Dent. Today* 1998;17,83-85
18. Catherine F. Poh, Samson Ng, Kenneth W. Berean, P. Michele Williams, Miriam P. Rosin, Lewei Zhang: Biopsy and Histopathologic Diagnosis of Oral Premalignant and Malignant Lesions. *JCDA* April 2008; 74: 3.
19. Michael A. Kahn, Lynn W. Solomon, J. Michael Hall, American Board of Oral and Maxillofacial Pathology <http://dental.tufts.edu/tops>.